

Liver metastases from a hard-to-find primary cancer

Metástases hepáticas de primário difícil de encontrar

Mondragao A¹, Ramos A R¹, Costa S², Barbedo M¹

¹Department of Internal Medicine, Centro Hospitalar Gaia e Espinho, Vila Nova de Gaia, Portugal. ²Department of General Surgery, Centro Hospitalar Gaia e Espinho, Vila nova de Gaia, Portugal

RESUMO

O cancro de primário desconhecido é responsável por cerca de 3-5% de todas as neoplasias malignas e é, portanto, um dos 10 diagnósticos de cancro mais frequentes. A tecnologia de imagem moderna e o estudo anatomopatológico desenvolvido (imuno-histoquímica, microscopia eletrónica e diagnóstico molecular) resultaram na melhoria do diagnóstico; no entanto, os primários permanecem ocultos na maioria dos doentes, mesmo pós-autópsia. Os locais mais comuns de origem são os tumores do pulmão e pâncreas. O cancro de origem desconhecida é diagnosticado num estadio metastático, conferindo um prognóstico desfavorável. O fígado é um dos órgãos mais comumente envolvido na doença metastática, que surge com mais frequência de primários no cólon. A colonoscopia é o gold standard para avaliação da mucosa do cólon e reto. É apresentado um doente de 64 anos, sem história médica de relevo, que recorreu ao serviço de urgência por dor no flanco direito. A ecografia abdominal revelou metastização hepática difusa. A tomografia computadorizada referia suspeita de espessamento do cólon ascendente mas a endoscopia e colonoscopia (com uma boa visibilidade da válvula ileocecal) não tinham alterações.

Palavras-chave: Colonoscopia; cancro colorretal; metástases hepáticas; cancro de primário desconhecido.

ABSTRACT

Metastatic Cancer of Unknown Primary Site (CUP) accounts for approximately 3-5% of all malignant neoplasms and is therefore one of the 10 most frequent cancer diagnoses. Modern imaging technology and extensive work-up with specific pathology investigations (immunohistochemistry, electron microscopy and molecular diagnosis) have resulted in some improvements in diagnosis; however, the primary site remains unknown in most patients, even on autopsy. The most prevalent sites of primary tumors origin are the lung and pancreas. CUP is diagnosed at a metastatic stage, conferring an unfavorable prognosis. The liver is one of the most common organs to be involved with metastatic disease, which arises most frequently from primary sites in the colon. A total colonoscopy is the gold standard for the evaluation of the colon. We present a 64-year-old man with no remarkable past medical history, which presented to the Emergency Service with right flank pain. The abdominal ultrasound revealed diffuse lesions suggestive of hepatic metastases. A computerized tomography (CT) scan showed thickening of ascending colon, but upper and lower endoscopies (with a good view of the ileocecal valve) and other diagnostic procedures were unremarkable.

Keywords: colonoscopy, unknown primary neoplasms, neoplasm metastasis, colorectal neoplasms

INTRODUCTION

Cancer of unknown primary site (CUP) is a well recognized clinical disorder, accounting for 3% to 5% of all malignant epithelial tumors^{1,2,3,4,5}. CUP represents a heterogeneous group of metastatic tumors for which no primary site can be detected following a thorough medical history, careful clinical examination and extensive diagnostic work-up^{1,5,7}. Diagnostic approaches to identify the primary site include radiological assessment, modern imaging technology (computed tomography, digital mammography, positron emission tomography), detailed histopathological examination and tumoral markers workup with specific immunohistochemistry^{1,2,5,7}. Upon detection of a metastasis of unknown origin, extensive diagnostic work-up is undertaken to optimize the treatment².

CUP is reported to be the seventh to eighth most frequent malignant cancer, and is the fourth most common cause of cancer death in both sexes³. Median age at presentation is 65–90 years^{3,4}. The disorder is slightly more common in men than in women, and predominantly affects adults (less than 1% of patients with diagnosed solid CUP are children)^{3,4}.

Most cases of CUP are carcinomas, which are divided into adenocarcinomas of well or moderate differentiation (60%), undifferentiated or poorly differentiated adenocarcinomas (30%), squamous-cell carcinomas (5%), and undifferentiated neoplasms (5%)^{3,7,9}. CUP may occasionally present as mixed tumors, adenocarcinoma with neuroendocrine components,

or sarcomatoid carcinoma^{5,9}. Autopsy helps to understand the diagnosis and natural history of CUP³. In some analysis studies from 1944 to 2000, the primary tumour was identified in 644 (73%) of 884 patients; the most common primaries were lung (27%) and pancreatic tumours (24%); tumours in the liver or bile duct (8%), kidney or adrenals (8%), colon or rectum (7%), genital system (7%), and stomach (6%) were also reported³. More than 50% of CUP patients present with multiple sites of involvement, while the rest have a single site, most commonly liver, bone, lung or lymph nodes^{6,10,11}. CUP is clinically characterized as an aggressive disease with early dissemination^{1,5}. In particular, the prognosis is favorable in CUP limited to lymph nodes and with histology other than adenocarcinoma^{4,5,8}.

Recent studies demonstrated familial clustering of CUP and the association of CUP with many other cancers, especially those originating from organs suspected to be responsible for many CUP diagnoses^{1,8}. Accordingly, CUP often occurred in relatives of patients with lung, colorectal (CRC) liver, ovary and kidney cancers, among others^{5,6,7}.

CASE REPORT

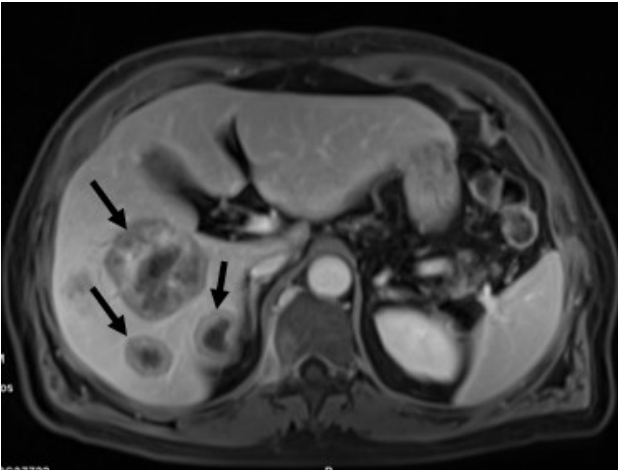
A 64-year-old man with dyslipidemia, benign prostatic hyperplasia and partial gastrectomy due to duodenal bleeding (30 years earlier) presented to the emergency department because of a right flank pain since 2 months before. The pain was colicky, moderate intensity, sometimes radiating to the

Correspondencia: anitamondragao@hotmail.com

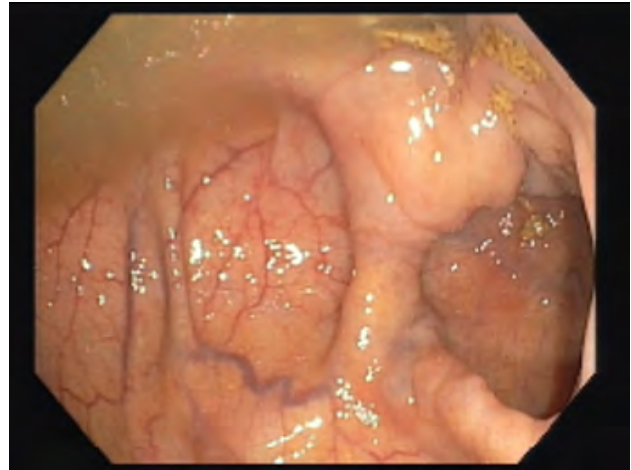
Como citar este artículo: Mondragao A, Ramos AR, Costa S, Barbedo M. Liver metastases from a hard-to-find primary cancer. *Galicía Clin* 2017; 78 (4): 159-162

Recibido:30/10/2016; Aceptado: 20/12/2016

Picture 1. Pelvis magnetic resonance imaging showing liver metastasis showing large lesions and heterogeneous enhancement (->).



Picture 2. Colonoscopy showing complete visualization of the ileocecal valve, with no lesions.



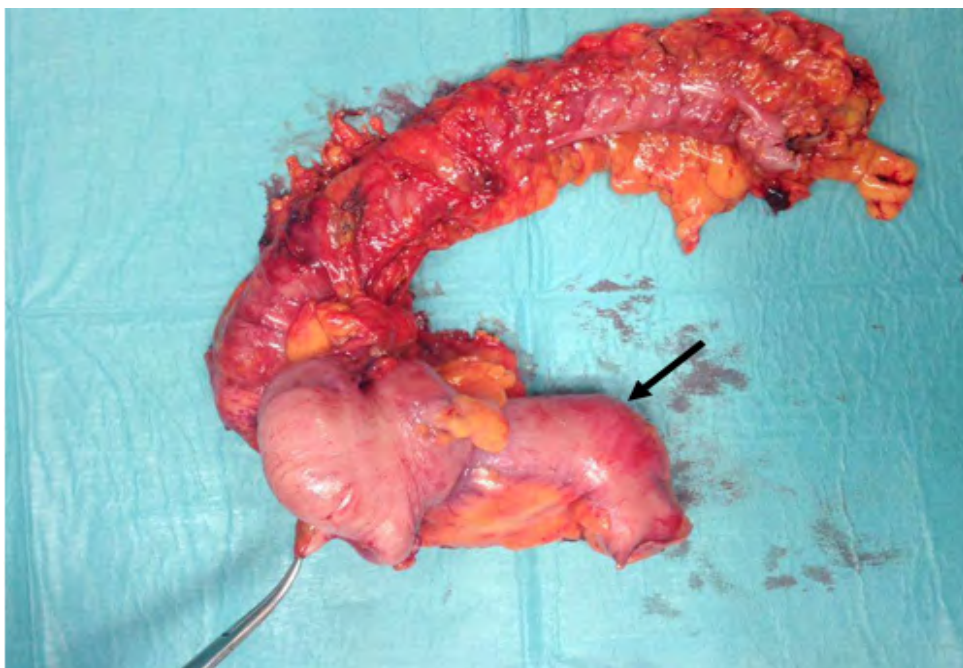
lower back, without aggravating or relieving factors. He was evaluated by several physicians who prescribed anti-viral and painkillers drugs, without achieving pain relief. Concomitantly, he complained about anorexia and weight loss (2 kg in 2 months, corresponding to 2.8% of body weight). No urinary or gastrointestinal symptoms were described, nor night sweats or blood loss in stool.

On physical examination, he was well hydrated, anicteric; abdomen was painful on deep palpation of the right flank and hypogastrium, with no signs of peritoneal irritation; hepatomegaly was palpable 4 cm below the costal margin, with irregular edges.

Laboratory tests revealed normal hemoglobin concentration 14.7 g/dL (normal range 13.0 - 18.0 g/dL); leukocyte count

$8.90 \times 10^3/\mu\text{L}$; platelet count $253 \times 10^3/\mu\text{L}$ (normal range $150 \times 10^3/\mu\text{L}$ to $450 \times 10^3/\mu\text{L}$). Kidney function and urine analysis were normal. Alanine aminotransferase, aspartate aminotransferase, gamma glutamyl transpeptidase and alkaline phosphatase were within normal limits. Tumor markers CA19.9, alpha fetoprotein and prostate-specific antigen were also normal. Abdominal ultrasound revealed many nodules scattered over the right and left liver lobes; suggestive of metastases. An abdominal computerized tomography (CT) scan described, in addition to liver findings, a stenotic lesion of the proximal colon compatible with probable neo-formative condition, defined like a concentric wall irregular thickening involving 4.5cm in length of colonic segment and leading to reduced colonic lumen. Pelvic magnetic resonance imaging

Picture 3. Surgical piece in anatomic position, with distended terminal ileum (->). The Kelly forceps is at the ileocecal appendix end. The retraction of the colon is conditioned by ulcerated ascending colon cancer.



(MRI) showed hepatic lesions compatible with metastases (figure 1). Under suspicion of digestive cancer, he underwent full colonoscopy, viewing the ileocecal valve. No lesions, including polyps or neo-formations, were found throughout the colon (figure 2). Upper endoscopy was also normal.

An ultrasound-guided liver node biopsy was performed, showing histology compatible with adenocarcinoma of metastatic colorectal source. Another colonoscopy with good preparation and under sedation was carried out, with good visualization of cecum, and performed by an experienced gastroenterologist. Nevertheless, no findings were identified. The patient was discussed in multidisciplinary round including Internal Medicine, General Surgery and Medical Oncology, and a diagnostic exploratory laparoscopy was decided, since the complementary diagnostic procedures remained inconclusive. The diagnostic laparoscopy confirmed liver metastasis, no free fluid or obvious peritoneal carcinomatosis, and the presence of a cecum neoplasia with dilation of the proximal small bowel. He underwent laparotomy and, despite the liver metastasis, a radical right hemicolectomy was performed because of the small bowel occlusion risk, in the absence of visible peritoneal carcinomatosis -cT3N1M1 (according to Tumor Node Metastases [TNM] staging system, pre-treatment clinical classification designated cTNM: T3 – tumor invades through muscularis propria into subserosa, N1 - regional lymph node metastases, M1 - distant metastases).

No complications appeared during postoperative period. The pathology of the surgical specimen identified moderately differentiated adenocarcinoma of the cecum and ileocecal valve, with venous vascular invasion, metastases in 11 of 24 lymph nodes and metastatic focus on the great epiploon -pT3N2b M1b, Stage IVC (post-surgical histopathological classification designated pTNM: T3 - increasing size and/or local extent of the primary tumor histologically, N2b - tumor cells found in 7 or more regional lymph nodes, M1b - distant metastases microscopically at any sites other than the cecum or ileocecal valve; stage IVC: the cancer has spread outside the abdominal area to distant sites of the body (any T, any N, M1b).

After surgery, the patient was discussed in a multidisciplinary Oncology group and underwent chemotherapy with Folfiri® and Bevacizumab. After 20 months of follow-up, patient presents good general condition, without gastrointestinal symptoms and controlled pain. The hepatic metastases are stable under well-tolerated palliative chemotherapy.

DISCUSSION

CUP is one of the 10 most prevalent malignancies^{4,5}. Patients in whom a site of origin can be ascribed have better outcomes than those in which the primary tumor remains unidentified^{4,8}. The primary site becomes obvious in only 25% of patients during their lifetime⁴. At necropsy, however, the primary cancer can be identified in 70% of all patients^{4,5}. Autopsy data suggest that the the most common sites of primary cancers origin are the lung (30%) and the pancreas (20%)⁹, followed by liver, gastrointestinal tract, kidney and breast⁵.

In this clinical case, the initial presentation was abdominal pain with ultrasound and CT revealing lesions suggestive of liver metastases. The imaging and endoscopic tests were not conclusive: the stenotic lesion of the ascending colon initially observed in abdominal CT was not visualized in both colonoscopies, considered the gold standard test for detection of CRC, with the highest sensitivity and specificity¹². Detection rates are highly related to the experience of the operator, adequacy of the bowel preparation, and even the time taken on examination^{12,14}. Otherwise, during the past 30 years, the accuracy of detecting primary cancer by CT or MRI has increased from 11–26% to 33–55%^{3,4}. Specifically, CT colonography and endoscopic capsule has gained much attention for its high sensitivity for CRC, in some cases^{12,13}.

The liver is one of the most common organs to be involved with metastatic disease of CUP, which arises most frequently from primary sites in the colon, breast, lung, pancreas, and stomach⁸. The accurate detection of metastatic disease at the time of diagnosis or during the course of treatment remains crucial to patient management^{8,10}. Early identification of primary tumor, provides the opportunity for resection which, at least in cases of CRC, has been shown to prolong survival^{8,9}.

CRC is the fourth most common cancer (in the West) and the second most common cause of cancer-related mortality after lung cancer (in Europe and North America)¹³. More than 50% of patients will develop liver metastases during their lifespan¹³. Presentation of liver metastasis may be either synchronous or metachronous^{13,15}. Synchronous disease, commonly defined as liver metastases occurring within 12 months of the diagnosis of colon or rectal primary tumor, represents 13 to 25% of newly diagnosed CRC liver metastases^{14,15}. Metachronous disease develops in 20 to 25% of patients¹⁵. Patients with synchronous CRC liver metastases are thought to have a worse prognosis than those with metachronous disease^{6,7,11}.

Almost half of patients undergoing resection for primary CRC will eventually develop metachronous liver metastases^{11,15}. Thanks to improvements in chemotherapies and biological agents, survival is about 54 months^{6,13,15}. Unlike many other types of cancer, the presence of distant metastases from CRC does not preclude curative treatment^{6,11}. Hepatic resection is currently the most effective form of therapy for CRC metastases confined to the liver¹⁵. However, only a minority of patients with liver metastases is eligible to surgery^{6,7,11}. Recent progress including new chemotherapeutic regimens, ablative techniques and interventional radiology may permit an increase in the number of patients that can be treated with curative intent^{6,7,11,14,15}.

Considering 80% of patients with CRC hepatic metastases presenting with unresectable disease, systemic chemotherapy represents the main and often the only form of therapy for many patients. Chemotherapy also plays a role in transforming patients with unresectable disease into resection candidates¹⁵. Most high-volume centers report a 5-year survival rate of 30 to 40% following resection for hepatic CRC metastases.

In this clinical case, at the time of laparoscopy, the diagnosis of CRC was unknown. Stenosis and proximal dilation of the ileum (and the absence of peritoneal carcinomatosis) were revealed during laparoscopy, leading to perform a radical hemicolectomy. Multiple liver metastases were not eligible for resection. Therefore, after colon surgery, the patient received palliative chemotherapy.

CONCLUSION

This clinical case and review emphasizes the importance of a multidisciplinary approach for the early suspicion and diagnosis, as well as optimal management of CUP. The new endoscopic techniques along with recent developments in radiological imaging suggest that the investigation of CUP could define a new patient-based diagnostic paradigm and decision making^{13,14}.

REFERENCES

1. Pavidis N, Briasoulis E, Hainsworth J, Greco FA. Diagnostic and Therapeutic management of cancer of an unknown Primary. *Eur J Cancer* 2003; 39: 1990-2005.
2. Briasoulis E, Pavidis N, Felip E. Cancers of Unknown Primary site: ESMO Clinical Recommendation for Diagnosis, treatment and Follow-up. *Ann Oncol* 2008; 19 Suppl 2:ii106-7.
3. Pavidis N, Pentheroudakis G. Cancer of Unknown Primary Site. *Lancet*. 2012; 379:1428-35.
4. Bugat R, Bataillard A, Lesimple T, Voigt JJ, Culine S, Lortholary A, et al. Summary of the Standards, Options and Recommendations for the management of patients with carcinoma of unknown primary site. *Br J Cancer* 2003;89:Suppl 1:S59-66.
5. Varadhachary G. Carcinoma of Unknown Primary Origin. *Gastrointest Cancer Res*. 2007;1:229-235.
6. Adam R, De Gramont A, Fiqueras J, Guthrie A, Kokudo N, Kunstlinger F et al. The Oncosurgery Approach to Managing Liver Metastases from Colorectal Cancer: A Multidisciplinary International Consensus. *Oncologist* 2012;17: 1225-39.
7. Varadhachary GR, Greco FA. Overview of Patient Management and Future Directions in Unknown Primary Carcinoma. *Semin Oncol* 2009; 36: 75-80.
8. Sica GT, Ji H, Ros PR. CT and MR Imaging of Hepatic Metastases. *AJR Am J Roentgenol* 2000;174:691-698.
9. Varadhachary GR, Raber MN. Cancer of Unknown Primary Site. *N Engl J Med* 2014;371:757-65.
10. Danet IM, Semelka RC, Leonardou P, Braga L, Vaidean G, Woosley JT et al. Spectrum of MRI Appearances of Untreated Metastases of the Liver. *AJR Am J Roentgenol* 2003;181:809-817.
11. Penna C, Nordlinger B. Surgery of liver metastases from colorectal cancer: new promises. *Br Med Bull* 2002;64:127-140.
12. Pickhardt PJ, Hassan C, Halligan S, Marmo R. Colorectal Cancer: CT Colonography and Colonoscopy for Detection – Systematic Review and Meta-Analysis. *Radiology*. 2011;259:393-405.
13. Misiakos EP, Karidis NP, Kouraklis G. Current treatment for colorectal liver metastases. *World J Gastroenterol*. 2011; 17:4067-4075.
14. Rex DK, Adler SN, Aisenberg J, Burch W Jr, Cerretero C, Chowders Y et al. Accuracy of Capsule Colonoscopy in Detecting Colorectal Polyps in a Screening Population. *Gastroenterology* 2015;148:948-957.
15. Seth KR, Clary BM. Management of Hepatic Metastases from Colorectal Cancer. *Clin Colon Rectal Surg*. 2005;18:215-223.