

Lesión cutánea del muslo como expresión metastásica de neoplasia mamaria

Skin lesion of the thigh as a metastatic expression of breast neoplasia

Raquel Afonso, Joana Urbano

Internal Medicine. Unidade Local de Saúde do Alto Minho. Viana do Castelo (Portugal)

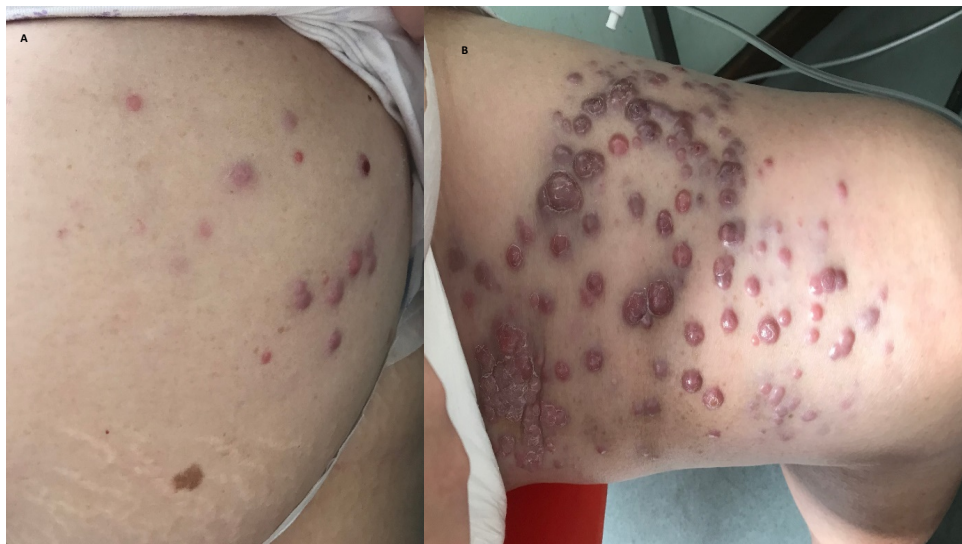


Figure 1: Cutaneous metastasization of breast carcinoma in the abdomen (1A) and left thigh (1B).

CASE DESCRIPTION

An 87-year-old woman, diagnosed with stage IIIA invasive carcinoma of the left breast (T3N2M0) 8 months ago, under hormone treatment (refused surgery), presented to the emergency service with nodular skin lesions on the abdomen and right thigh with 2 months of evolution (Figure 1), very painful, requiring daily analgesia with non-steroidal anti-inflammatory drugs (NSAIDs); and decreased urine output for 1 week.

The patient was hospitalized for severe oliguric acute kidney injury with metabolic acidemia, in the context of excessive consumption of NSAIDs and for clarification of skin lesions. Skin biopsy was performed, with anatomopathological examination suggesting infiltration of the dermis by malignant neoplasm with characteristics of breast carcinoma.

Re-staging showed no metastasis to other organs.

Despite fluid therapy, the patient had an unfavorable clinical evolution, and was not considered a candidate for renal function support therapy, and died following renal dysfunction and metabolic acidosis.

Cutaneous involvement by neoplasms is uncommon - 0.5 to 9% of cases^{1,2}. In relation to breast cancer, cutaneous metastases occur in only 2% of patients and are an indicator of poor prognosis^{1,2}, as in the case described.

When present, metastasization occurs by continuity, and is most often seen in the thorax¹. In the present case, metastases were found in the abdomen and lower limb, which are less typical sites; the exuberance of the skin lesions is also noteworthy.

CONFLICTS OF INTEREST

The authors declare that there were no conflicts of interest in carrying out the present work.

FUNDING SOURCES

There were no external funding sources for this article.

ETHICAL ASPECTS

All participants submitted a consent form to be included in this study.

REFERENCES

1. Wong CY, Helm MA, Helm TN, Zeitouni N. Patterns of skin metastases: a review of 25 years' experience at a single cancer center. *Int J Dermatol.* 2014;53(1):56-60.
2. Krathen RA, Orengo IF, Rosen T. Cutaneous metastasis: a meta-analysis of data. *South Med J.* 2003;96(2):164-7.

Correspondencia: anaraquel_75@hotmail.com

Cómo citar este artículo: Afonso R, Urbano J.

Skin lesion of the thigh as a metastatic expression of breast neoplasia. *Galicia Clin* 2023; 84-4: 35.

Recibido: 31/01/2023 ; Aceptado: 21/03/2023 // <https://doi.org/10.22546/71/4070>